


Article

Acute Hepatic and Renal Toxicity Assessment of *Euphorbia huanchahana* (Klotzsch & Garcke) Boissier (Huachangana) in Holtzman Rats

Graciela Villafuerte ¹, Daniel Ñañez ¹, Luis M. Félix ², Marcia M. Moya-Salazar ^{1,3,4}, Ernesto R. Torres-Véliz ², Antonio G. Ramos ¹, Hans Contreras-Pulache ⁵ and Jeel Moya-Salazar ^{3,4,6,*} 

- ¹ Faculty of Pharmacy and Biochemistry, Universidad Norbert Wiener, Lima 15001, Peru; artesfreshma@gmail.com (G.V.); daniel.nanez@uwiener.edu.pe (D.Ñ.); c23359@utp.edu.pe (M.M.M.-S.); a2018200823@uwiener.edu.pe (A.G.R.)
- ² Faculty of Pharmacy and Biochemistry, Universidad Nacional Mayor de San Marcos, Lima 15001, Peru; lfelixv@unmsm.edu.pe (L.M.F.); etorresve@unmsm.edu.pe (E.R.T.-V.)
- ³ Qualitative Unit, Nesh Hubbs, Lima 51007, Peru
- ⁴ Faculties of Health Science, Universidad Tecnológica del Perú, Lima 15001, Peru
- ⁵ South American Center for Education and Research in Public Health, Universidad Norbert Wiener, Lima 51001, Peru; hans.contreras@uwiener.edu.pe
- ⁶ Graduate School, Universidad Norbert Wiener, Lima 51001, Peru
- * Correspondence: jeel.moya@uwiener.edu.pe



Citation: Villafuerte, G.; Ñañez, D.; Félix, L.M.; Moya-Salazar, M.M.; Torres-Véliz, E.R.; Ramos, A.G.; Contreras-Pulache, H.; Moya-Salazar, J. Acute Hepatic and Renal Toxicity Assessment of *Euphorbia huanchahana* (Klotzsch & Garcke) Boissier (Huachangana) in Holtzman Rats. *Processes* **2022**, *10*, 1286. <https://doi.org/10.3390/pr10071286>

Academic Editor: Jaime Yáñez

Received: 18 May 2022

Accepted: 18 June 2022

Published: 30 June 2022

Publisher's Note: MDPI stays neutral with regard to jurisdictional claims in published maps and institutional affiliations.



Copyright: © 2022 by the authors. Licensee MDPI, Basel, Switzerland. This article is an open access article distributed under the terms and conditions of the Creative Commons Attribution (CC BY) license (<https://creativecommons.org/licenses/by/4.0/>).

Abstract: Background: *Euphorbia huachahana* (Klotzsch & Garcke) Boissier (Huachangana) (EhKGBh) has been used for over a century for medicinal purposes in the Peruvian population; however, its safety and possible toxic effects of use have not been reported. The purpose of this study was to determine the acute hepatic and renal toxicity of EhKGBh in Holtzman rats. Methods: Analytical and experimental study. The population consisted of 52 rats of both sexes weighing between 300 and 350 g divided into four groups: G1 and G2 EhKGBh groups (26 rats each) and two control groups (10 rats each). The experimental group was administered EhKGBh at a single dose of 2000 mg/kg P.O. to demonstrate toxicity during the 14-day follow-up. A daily assessment of alanine aminotransferase (ALT), aspartate aminotransferase (AST), alkaline phosphatase (ALP), total bilirubin (TBIL), and conjugated bilirubin (CBIL) was performed. Results: Evaluation of the liver tissue showed mild changes in inflammation, predominantly vascular, with small clots. Kidney tissue did not show inflammatory or necrotic changes. However, we showed differences in the weight of the rats between both groups ($p < 0.004$) and significant increases in TBIL (0.98–1.07 mg/dL), CBIL (0.43–0.45 mg/dL), AST (126.4–141.8 U/L), and ALP (254–298 U/L) but not ALT (39.7–41.1 U/L) ($p < 0.05$). Conclusion: The single dose of EhKGBh extract at 2000 mg/kg has no toxicity, and there is no change in tissue toxicity during the 14-day follow-up.

Keywords: toxicity; kidney; liver; LD50; acute; in vivo studies

1. Introduction

Humans have been living with derivatives of plants, making them part of their needs, using them in ancient rituals and cults, and dealing with disease empirically. As a result, plants are no longer just part of the forest but become part of medicinal gardens and orchards and gradually began to provide natural medicines to humans [1].

Despite the current technological revolution and advancements in the industry, the World Health Organization (WHO) estimates that about 80% of the population in low- and middle-income countries (LMICs) are almost entirely dependent on medicines for primary health care needs. As a result, 67% of medicinal plants used globally come from LMIC [2,3]. This practice is associated with empiricism in many cases, and there is a lack of chemical, clinical, and epidemiological studies that reliably confirm the physiological

effects of the responsible active ingredients, since ~25% of existing drugs are obtained from plant extracts, or it has been synthesized from substances found in phytochemical research [4].

Poisoning by medicinal plants can occur due to the malpractice of an innocuous substance of natural origin, as a consequence of the absorption of an excessive quantity of a phytosanitary product in a short interval of time. The fact that herbal remedies are natural products does not mean they are completely safe, as some plants can have as strong an effect as some drugs and cause adverse events depending on the consumption of the plant [5]. Currently, cases of intoxication by medicinal plants that can present an epidemic or fatal character are rare [6]. However, natural products can occasionally cause problems, because they are accidentally present in foods in higher-than-normal concentrations, or toxic species can be confused with harmless species, such as some edible mushrooms, and can even cause death [7]. In addition, very few cases are reported by the consumer group due to ignorance and lack of identification of toxic effects produced by several medicinal products marketed mainly in LMICs, without toxicity studies being conducted.

Euphorbia huanchahana (Klotzch & Garcke) Boissier (*Huachangana*) belongs to the *Euphorbiaceae* family, one of the largest, most complex, and diverse plant families in the world, with great potential for application, with more than 1100 species, native or naturalized [8]. Developing in different habitats, Peru has more than 323 species and 61 genera of about 2000 and 7000 species [9]. From *Euphorbia huanchahana* (Klotzch & Garcke) Boissier (*Huachangana*), food can be prepared, castor oil can be extracted, and its pharmacological use is mainly as a purgative, hypoglycemic and antimicrobial. The indications for the consumption of *Euphorbia huanchahana* (Klotzch & Garcke) Boissier (*Huachangana*) are in a single dose as a purgative or, if necessary, in two doses. The most frequent route of consumption is oral, and the preparation may include infusions taken on an empty stomach [10].

Previous investigations have identified possible toxic concentrations of *Euphorbia lateriflora* (Schum and Thonn) [11] and *Euphorbia heterophylla* L. [12] in animal models, but the toxic effects of *Euphorbia huanchahana* (Klotzch & Garcke) Boissier (*Huachangana*) have not been elucidated. Although toxicity tests for various plants are available in a large number of countries, there are no data on the potential toxicity of many medicinal species in Peru [13]. In addition, since many populations consume the fresh tuber of *Euphorbia huanchahana* without a specific measure of consumption per person, the effects derived from the consumption of *Euphorbia huanchahana* are uncertain and potential threats.

Although the consumption of *Euphorbia huanchahana* (Klotzch & Garcke) Boissier (*Huachangana*) is not exclusive to certain Peruvian regions, rural or peri-urban populations with limited economic resources use this plant as a treatment for constipation without a medical prescription, with doses little, exact, and standardized, and without assessing the possible adverse effects that its use and abuse can cause in the short and long term [14]. Hence, here we determine the acute hepatic and renal toxicity of *Euphorbia huanchahana* (Klotzch & Garcke) Boissier (*Huachangana*) in Holtzman rats.

2. Materials and Methods

2.1. Study Design and Animal for Experimentation

We designed an experimental study in a total of 52 rats (28 females) strain Balb/C53/CNPB species "Holtzman" of both sexes acquired from the National Institute of Health of Peru. The rats weighed between 177 and 280 g and were stored for 50 days in the Norbert Wiener University animal facility during the entire experiment at room temperature ($\sim 22\text{ }^{\circ}\text{C} \pm 3$) with 12 h of light and 12 h of darkness and a relative humidity of 65%. They had access to water and food ad libitum (all day).

2.2. Obtaining the Ethanolic Extract, Solubility Test and Phytochemical Analysis

Euphorbia huanchahana (Klotzsch & Garcke) Boissier (*Huachangana*) was obtained directly from the community of Vichavichay-Castrovirreyna Town in the Municipality of Huanavelica (about 3706 m above sea level) in Southern Peru. Botanical identification was

performed at the Universidad Nacional Mayor de San Marcos' Museum of Natural History prior to the trial, and voucher specimens were preserved. Initially, we obtained the ethanolic extract by maceration following a previous protocol [15]. Four kilograms of the tuber were included, which were macerated with ethanol 70° per 7 days in the dark at room temperature. The supernatant evaporated at 40 °C (104°F), and the final sample was 320 g.

To describe the qualitative processes of dissolution with solvents of increasing polarity, the solubility test was carried out following a previous protocol [16]. We used distilled water, ethanol, methanol, n-butanol, chloroform, acetone, ethyl acetate, n-hexane, ether, and benzene (Figure A1).

The qualitative phytochemical profile to identify metabolites was carried out with the fractionation method in terms of the relationship between the chemical composition of the plant and the pharmacological effect described in the preclinical models carried out [17,18]. A weight of 1 g of *Euphorbia huanchahana* (Klotzsch & Garcke) Boissier (*huachangana*) sample was dissolved in 20 mL of ethanol, and add 1 mL of each reagent described in Figure A2 to this mixture for the identification of the primary and secondary metabolites.

2.3. Toxicologic Assay

The toxicity bioassays were focused on the analysis of hepatic and renal alteration in Holtzman rats. These tests were carried out following the limit test of the Environmental Protection Agency (EPA) 870.1100, the procedures and international recommendations established in the Manual of Techniques and Methods of Research in Human Nutrition, Ethical Standards of the European Union for Animal Experimentation, Guide for the Care and Use of Laboratory Animals, and the Guideline for the Testing of Chemical Products OECD/OECD 423 classification method for acute toxicity oral toxicity [19–21].

The rats were weighed and housed in their respective cages, according to the corresponding group. The food intake used was standard rat chow (barley), and the drink provided was the liquid water ad libitum. At the time of the toxicity bioassay, the average body weight of the rats was 225 g ± 2.66 g (female rats) and 276 g ± 2.94 g (male rats). Fifty-two Holtzman rats were divided into 4 groups according to gender: G1 (16 females), G2 (16 males), G3 (10 control females), and G4 (10 control males) during the acclimation period of 7 days. The protocol is outlined in Figure 1.

We prepared 8314 g of dry extract of *Euphorbia huanchahana* (Klotzsch & Garcke) Boissier (*huachangana*) following a previous protocol [22]. We administered between 2.76 and 3.12 mL/kg/p.o./q.d. to each rat of the experimental group (G1 and G2), with a total of 2000 mg/kg of *Euphorbia huanchahana* (Klotzsch & Garcke) Boissier (*huachangana*) [23]. Following a single dose, the animals were observed for an additional 14 days to detect clinical signs of toxicity. Weight control was performed on days 1, 7, and 14. The observations of the experimental animals were after administering the dose and, according to the body weight of the rats, the amount of extract (ml) that was administered to determine the lethal dose (LD50), as well as the appearance of the signs related to the general condition of rats using the following parameters (appearance of hairs, lacrimation, apnea, dyspnea, salivation, tremor, drowsiness, lethargy, nasal noise, epistaxis and seizures, ataxia, diarrhea, and dehydration) [24]. The LD50 was estimated by administering the extract solution intraperitoneally at doses of 55, 155, 475, 950, 1500, 2000, 2750, 3200, 4500, 5700, and 6250 mg/kg. Adverse behavioral effects were observed at high doses, so the LD50 for *Euphorbia huanchahana* (Klotzsch & Garcke) Boissier (*huachangana*) was determined to be 2000.12 ± 140.2 mg/kg.

2.4. Hepatic Biomarkers and Histopathological Analysis

After the observation period, the blood sampling and organs extraction was carried out in the Pharmacology Laboratory of the Universidad Nacional Mayor de San Marcos. The liver biochemical profile that includes alanine aminotransferase (ALT), aspartate aminotransferase (AST), alkaline phosphatase (ALP), glutamyl transpeptidase (GGT), total bilirubin (TBIL), unconjugated bilirubin (UBIL), conjugated bilirubin (CBIL), albumin

(ALB), total proteins (TP), and globulins (GLB) was assessed following a protocol previously developed in Peru [25,26]. For all assays, we used reagents and equipment (Autoanalyzer BA400) from Biosystems (Biosystems S.A., Barcelona, Spain).

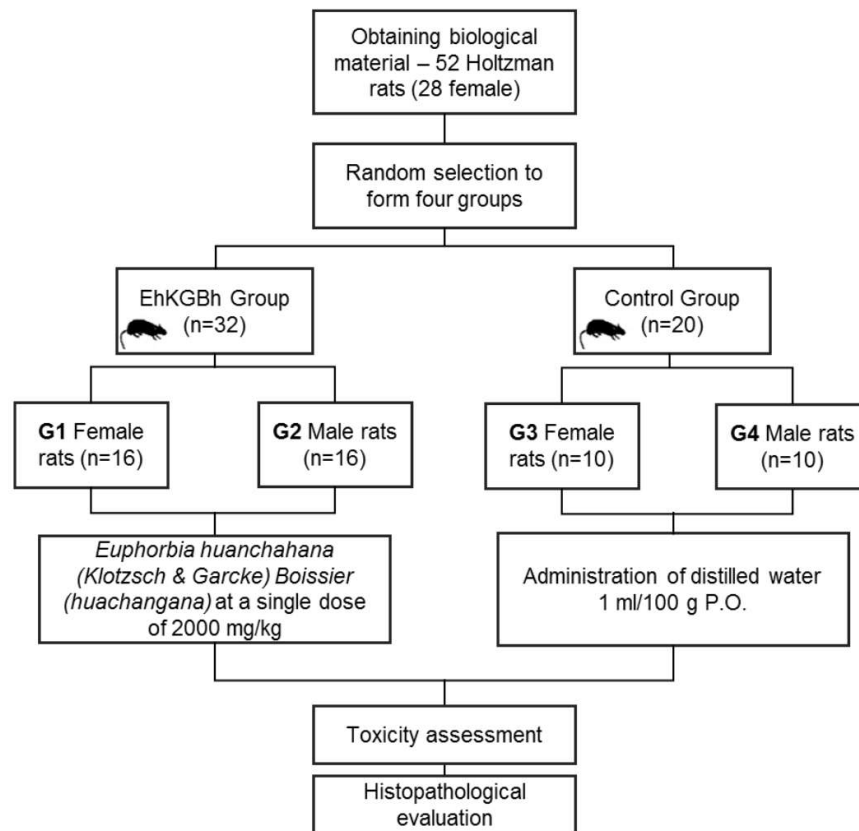


Figure 1. Study trial flowchart of the study. The rats were randomly assigned to each group according to their sex. Experimental groups G1 and G2 were administered *Euphorbia huanchahana* (Klotzsch & Garcke) Boissier (*huachangana*) (EhKGBh) at a single dose of 2000 mg/kg. Both groups had a follow-up of 14 days.

Histopathological analysis of the liver and kidney of Holtzman rats was developed based on the Cui protocol in 2010 [27]; for tissue processing (i.e., sampling, fixation, microtomy, etc.); and Culling's staining and montage techniques [28]. The indicators of toxicity were edema, intracellular accumulations, vascular congestion, necrosis, and hemorrhages. Histopathological studies were performed at the Central Clinical Pathology Laboratory of the Arzobispo Loayza National Hospital.

2.5. Data Analysis

Data collection and analysis was performed in SPSS (Armonk, NY, USA) v24.0 for Windows. Initially, descriptive statistics were performed with the estimation of frequencies for the categorical variables, and the mean and standard deviation for the continuous variables. In Vivo data were weight and physiological response to the administration of *Euphorbia huanchahana* (Klotzsch & Garcke) Boissier (*huachangana*). Histological data were collected after evaluation by three expert pathologists who agreed on inflammatory changes in the liver and kidneys. In order to determine the significant difference of the variables in groups and between groups (error), the measurement of the quantitative variable (weights of male and female rats) parametric and nonparametric techniques were used. For the comparison of the parameters between the control and experimental groups by sex, the Mann–Whitney *U* test was used and, on the other hand, the comparisons of changes in

the concentrations the of liver profile markers were made using the paired-Student's *t*-test. Significance thresholds were set for both cases at 5% ($\alpha = 0.05$) and 95% confidence interval ($1 - \alpha = 0.95$).

3. Results

3.1. Biochemical Assay

Euphorbia huanchahana (Klotzsch & Garcke) Boissier (*huachangana*) was soluble in polar solvents such as alcohol, and a phytochemical analysis did not reveal concentrations of steroids and/or triterpenes (negative Liebermann-Burchard test) (Figure 2).

Reagent	Metabolites	Results	Solvent	Result
Molish	Sugars	■	Distilled water	■
Fehling A and B	Reducing sugars	■	Ethanol	■
Benedict	Reducing sugars	■	methanol	■
Ninhydrin	Free-amino group	■	n-Butanol	■
Ferric trichloride 1%	Phenolic compounds	■	Chloroform	■
Gelatin 1% /NaOH 1%	Tannins	■	Acetone	■
Shinoda	Flavonoids	■	Ethyl acetate	■
Aluminum trichloride 1%	Flavonoids	■	n-Hexane	■
Balchet	Sesquiterpene lactones	■	Ethyl ether	■
Liebermann- Bourchard	Steroids and/or triterpenes	■	Benzene	■
Borntranger	Quinones	■		
Dragendorff	Alkaloids	■		

Soluble/positive ■
Insoluble/negative ■

Figure 2. Results of the phytochemical and solubility analysis of *Euphorbia huanchahana* (Klotzsch & Garcke) Boissier (*huachangana*). The solubility and positivity results are shown in red boxes and negative results in green.

3.2. Changes and Liver and Renal Markers

Tables 1 and 2 show a comparison of the liver parameters in male and female rats treated with *Euphorbia huanchahana* (Klotzsch & Garcke) Boissier (*huachangana*). In male rats, the mean concentration of TBIL was 1.07 ± 0.21 mg/dL, DBIL was 0.45 ± 0.07 mg/dL, UBIL was 0.62 ± 0.18 mg/dL, AST was 141.8 ± 34.57 U/L, ALT was 41.16 ± 5.69 U/L, ALP was 298 ± 85.29 U/L, TP was 5.58 ± 0.57 mg/dL, ALB was 3.59 ± 0.31 mg/dL, GLB was 1.94 ± 0.51 mg/dL, and GGT was of 25.44 ± 9.04 mg/dL. We found differences in the increased concentration of TBIL ($p = 0.022$), DBIL ($p = 0.021$), AST ($p = 0.023$), ALP ($p = 0.023$), and TP ($p = 0.021$) in male rats treated with *Euphorbia huanchahana* (Klotzsch & Garcke) Boissier (*huachangana*) versus the controls (Table 1).

In female rats, the mean concentration of TBIL was 0.98 ± 0.16 mg/dL, DBIL was 0.43 ± 0.10 mg/dL, UBIL was 0.60 ± 0.12 mg/dL, AST was 126.43 ± 25.53 U/L, ALT was 39.79 ± 5.98 U/L, ALP was 254.75 ± 108.53 U/L, TP was 5.42 ± 0.41 mg/dL, ALB was 3.58 ± 0.25 mg/dL, GLB was 1.81 ± 0.35 mg/dL, and GGT was 25.06 ± 6.82 mg/dL. We found differences in the concentrations of TBIL ($p = 0.020$), DBIL ($p = 0.023$), AST ($p = 0.023$), ALP ($p = 0.023$), TP ($p = 0.023$), ALB ($p = 0.018$), GLB ($p = 0.031$), and GGT ($p = 0.033$) in female rats treated with *Euphorbia huanchahana* (Klotzsch & Garcke) Boissier (*huachangana*) versus the controls (Table 2).

During the 14-day follow-up period, half of the experimental group had slight changes in liver markers compared to the control group, while 8/10 of the female rats had changes in liver markers ($p < 0.05$). We found significant differences in the concentrations of liver markers between the genders of Holtzman rats ($p = 0.034$).

The results of normal or altered levels of liver markers are shown in Figure 3. Eighty eight percent and one hundred percent of Holtzman rats treated with the ethanolic extract of *Euphorbia huanchahana* (Klotzsch & Garcke) Boissier (*huachangana*) had high values of TBIL and CBIL, respectively. In addition, transaminase values were higher in all Holtzman

rats in the experimental group, and 63% of the rats had higher ALP concentrations. For TP, ALB, and GLB, we found a reduction of 75%, 13%, and 88% in the concentration, respectively.

Table 1. Concentration of liver markers between male rats from the control and experimental groups treated with *Euphorbia huanchahana* (Klotzsch & Garcke) Boissier (*huachangana*) (grupo EhKGBh).

Sex	Hepatic Marker	Groups	Mean	SD	U	p-Value
Male	TBIL (mg/dL)	Control	0.68	0.07	0.00	0.022
		EhKGBh	1.07	0.21		
	CBIL (mg/dL)	Control	0.16	0.11	0.00	0.021
		EhKGBh	0.45	0.07		
	UBIL (mg/dL)	Control	0.49	0.07	7.00	0.199
		EhKGBh	0.62	0.18		
	AST (U/L)	Control	76.24	7.69	0.00	0.023
		EhKGBh	141.80	34.57		
	ALT (U/L)	Control	31.61	10.15	5.00	0.119
		EhKGBh	41.16	5.69		
	ALP (U/L)	Control	142.11	53.20	0.00	0.023
		EhKGBh	298.00	85.29		
	TP (mg/dL)	Control	7.87	0.89	0.00	0.021
		EhKGBh	5.58	0.57		
	ALB (mg/dL)	Control	3.98	0.37	3.00	0.064
		EhKGBh	3.59	0.31		
GLB (mg/dL)	Control	3.41	0.81	3.00	0.063	
	EhKGBh	1.94	0.51			
GGT (mg/dL)	Control	36.00	19.80	9.00	0.320	
	EhKGBh	25.44	9.04			

Abbreviations: SD: Standard deviation, U: Mann–Whitney U, ALT: Alanine aminotransferase, AST: Aspartate aminotransferase, ALP: alkaline phosphatase, GGT: glutamyl transpeptidase, TBIL: total bilirubin, UBIL: unconjugated bilirubin, CBIL: conjugated bilirubin, ALB: albumin, TP: total proteins, and GLB: globulins.

Table 2. Concentrations of liver markers between female rats from the control and experimental groups treated with *Euphorbia huanchahana* (Klotzsch & Garcke) Boissier (*huachangana*) (grupo EhKGBh).

Sex	Hepatic Marker	Groups	Mean	SD	U	p-Value
Female	TBIL (mg/dL)	Control	0.35	0.04	0.00	0.020
		EhKGBh	0.98	0.16		
	CBIL (mg/dL)	Control	0.17	0.12	0.00	0.023
		EhKGBh	0.38	0.09		
	UBIL (mg/dL)	Control	0.43	0.10	3.00	0.062
		EhKGBh	0.60	0.12		
	AST (U/L)	Control	53.58	4.50	0.00	0.023
		EhKGBh	126.43	25.53		
	ALT (U/L)	Control	37.05	9.45	13.00	0.667
		EhKGBh	39.79	5.98		
	ALP (U/L)	Control	93.43	15.64	0.00	0.023
		EhKGBh	254.75	108.53		
	TP (mg/dL)	Control	6.49	0.01	0.00	0.023
		EhKGBh	5.42	0.41		
	ALB (mg/dL)	Control	4.25	0.12	0.00	0.018
		EhKGBh	3.58	0.25		
GLB (mg/dL)	Control	3.36	0.67	1.00	0.031	
	EhKGBh	1.81	0.35			
GGT (mg/dL)	Control	40.90	4.10	1.00	0.033	
	EhKGBh	22.06	6.82			

Abbreviations: SD: Standard deviation, U: Mann–Whitney U, ALT: Alanine aminotransferase, AST: Aspartate aminotransferase, ALP: alkaline phosphatase, GGT: glutamyl transpeptidase, TBIL: total bilirubin, UBIL: unconjugated bilirubin, CBIL: conjugated bilirubin, ALB: albumin, TP: total proteins, and GLB: globulins.

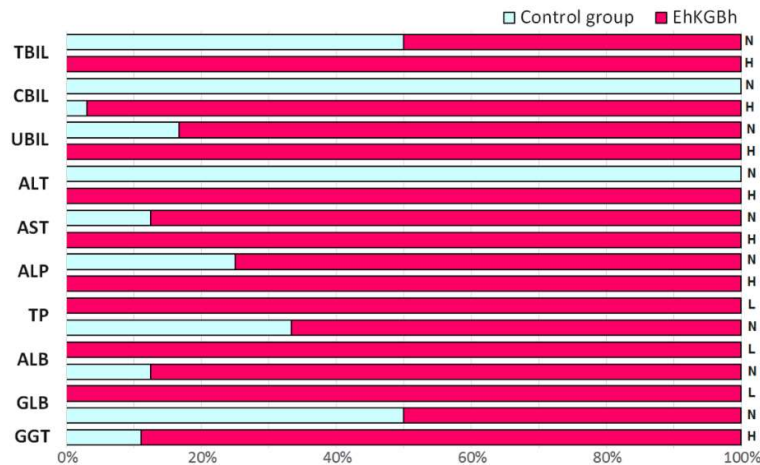


Figure 3. Normal (N), high (H), and decreased (L) levels of liver markers in Holtzman rats treated with *Euphorbia huanchahana* (Klotzsch & Garcke) Boissier (*huachangana*). The concentration distribution between the control group (light blue bars) and the experimental group (EhKGBh group—red bars) is shown in percentages (%). For each liver marker, the H, N, and L results are described.

The creatinine and urea concentrations were 0.7 ± 0.3 mg/dL and 23 ± 8.2 mg/dL, respectively. These values did not show a significant change between genders ($p = 0.112$) and were not different from the control group ($p = 0.087$).

3.3. Tracking the Weight Variation

The average body weight of male rats treated with *Euphorbia huanchahana* (Klotzsch & Garcke) Boissier (*huachangana*) was 254.25 ± 32.09 g on day 1, 267.56 ± 32.05 g on day 7, and 256.25 ± 31.70 g on day 14. The average body weight of female rats treated with *Euphorbia huanchahana* (Klotzsch & Garcke) Boissier (*huachangana*) was 221.56 ± 9.92 g, 235.06 ± 10.39 g, and 232.81 ± 11.54 g on days 1, 7, and 14, respectively (Table 3).

Table 3. Baseline characteristics of the body weights in rats treated with *Euphorbia huanchahana* (Klotzsch & Garcke) Boissier (*huachangana*) (EhKGBh group) compared to the control.

Sex	Parameter	Groups	Mean	SD	U	p-Value
Male	Weight day one (gr)	Control	266.50	0.71	14.00	0.779
		EhKGBh	254.25	32.09		
	Weight day seven (gr)	Control	270.50	2.12		
		EhKGBh	267.56	32.05		
Female	Weight day fourteen (g)	Control	264.00	1.41	13.50	0.724
		EhKGBh	256.25	31.70		
	Weight day one (gr)	Control	233.50	7.78		
		EhKGBh	221.56	9.93		
Weight day seven (gr)	Control	241.50	4.95	8.00	0.258	
	EhKGBh	235.06	10.39			
Weight day fourteen (g)	Control	236.50	4.95	9.50	0.354	
	EhKGBh	232.81	11.54			

As shown in Table 3, the body weights of male and female rats were monitored three times, and no significant difference was found between the males and females ($p > 0.05$). However, when we compared the overall body weights of the control and experimental groups, we found a difference between the days on which the body weights were assessed ($p < 0.004$). (Figure 4). We found a difference between the first and seventh days after *Euphorbia huanchahana* (Klotzsch & Garcke) Boissier (*huachangana*) administration ($p = 0.021$) but not on the fourteenth day ($p > 0.05$).

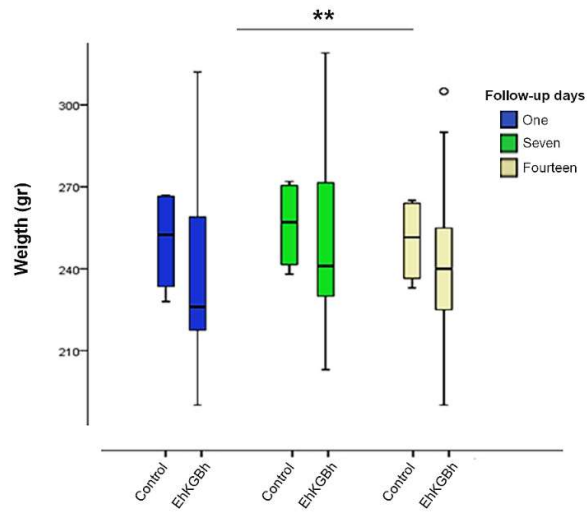


Figure 4. Differences in weights between the control group and the group treated with *Euphorbia huanchahana* (Klotzsch & Garcke) Boissier (*huachangana*) (EhKGBh). ** $p < 0.004$.

3.4. Tissue Toxicity

A histopathological analysis did not show major changes in the tissue structures of the liver and kidney of Holtzman rats treated with *Euphorbia huanchahana* (Klotzsch & Garcke) Boissier (*huachangana*). Figure 5 shows the tissue results for the control and experimental groups. The liver was evaluated at a dose of 2000 mg/kg, and mild inflammatory changes have been shown that mainly involved vascular alterations with small clots. We observed the preservation of the central lobular vein with empty spaces and free well-marked hepatocytes, central lobular space with compact peripheral central tissues, and empty spaces with the presence of fatty tissue. No inflammatory or necrotic alterations were found in the renal tissue.

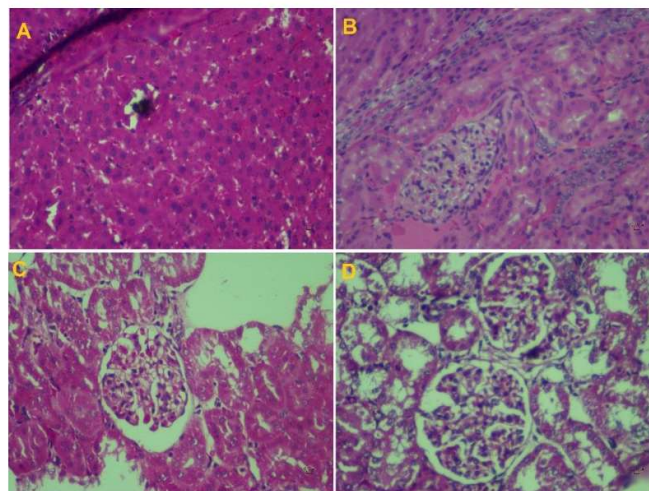


Figure 5. Histopathological findings of the livers (A,B) and kidneys (C,D) of Holtzman rats. (A) Sample of the experimental group treated with *Euphorbia huanchahana* (Klotzsch & Garcke) Boissier (*huachangana*), where an artery occluded by thrombosis, central lobular vein with congestive channels, and Kupffer's capsules preserved without hemorrhage were found (100×); (B) Control sample with Kupffer cells, central biliary vein, preserved central lobular vein, clean, clear without edema (100×). (C) Kidney sample from the experimental group treated with *Euphorbia huanchahana* (Klotzsch & Garcke) Boissier (*huachangana*) without inflammatory or congestive changes (100×). (D) Control group sample of the kidneys showing preserved cellular architecture (100×).

4. Discussion

We report increases in liver marker concentrations and changes in body weight in a group of Holtzman rats treated with the extract during a 14-day follow-up period. This preclinical study determined that the extract of *Euphorbia huanchahana* (Klotzsch & Garcke) Boissier (*Huachangana*) did not produce acute hepatorenal toxicity at a single dose of 2000 mg/kg.

Currently, the growing interest in medicinal plants has resulted in an unexpected boom in ethnobotany, phytotherapy, and phytochemistry in both complementary medicine practice and academia [29]. Medicinal plants have been used for food or healing purposes, which has increased the number of consumers and, therefore, adverse reactions and interactions with their consumption [30]. In Peru, *Euphorbia huanchahana* (Klotzsch & Garcke) Boissier (*Huachangana*) has been used for over 100 years as an effective laxative but has some adverse effects such as abdominal pain and intestinal contractions [31]. Given its empirical use, mainly in rural communities, its anthelmintic and antimicrobial properties have also been evaluated, with moderate community importance [32]. Despite its historical use, and as phylogenetic studies have recently described a subgenus of *Euphorbia*, toxicity testing is on the rise and has shown little or no toxicity capability at controlled doses [1]. In this study, post-mortem results indicate slight changes corresponding to the metabolic state of active ingredient processing. These include bile duct tamponade, peripheral hemorrhagic space, and damage to the centrilobular space.

These histopathological findings are not major pathological changes that have caused liver and kidney damage. Hence, the ethanolic extract of *Euphorbia huanchahana* (Klotzsch & Garcke) Boissier (*huachangana*) as a single dose of 2000 mg/kg did not cause lesions or cellular degeneration in the liver and kidney, which was consistent with previous studies [33,34]. However, we report changes in the concentrations of the liver function markers. We demonstrated higher mean concentrations of BILT (1.07 mg/dL vs. the control 0.68 mg/dL) and CBIL (0.38 vs. the control 0.17 mg/dL) in the experimental group. Other parameters showed significant differences in AST, ALP, and TP in male Holtzman rats, while, in female rats, we also saw significant increases in ALB, GLB, and GGT. These changes indicate hepatic compromise during follow-up and may indicate an imbalance in liver function linked to the administration of *Euphorbia huanchahana* (Klotzsch & Garcke) Boissier (*huachangana*). Although these changes may indicate changes in the liver function, tissue damage is not evident, and these changes may be related to acute inflammatory processes, consistent with previous studies [9,11,33,35–37]. Further research is required to understand whether these changes are related to inflammatory processes or whether there is transient localized liver injury that is resolved during follow-up.

On the other hand, the ethanolic extract of *Euphorbia huanchahana* (Klotzsch & Garcke) Boissier (*huachangana*) has polar phytochemicals, in agreement with previous studies [10,14]. Likewise, the analysis of the qualitative phytochemical profile of the extract showed the presence of polar metabolites (i.e., carbohydrates, reducing sugars, free amino groups, phenolic compounds, flavonoids, etc.), which is favored with the use of a solvent such as ethanol. These findings are consistent with those reported by Lock [17], Ñañez et al., [14], and Miranda [38]. Furthermore, the same composition has been demonstrated in other species of the same genus of *Euphorbia*, as pointed out by Castillo et al. [39], Collave [40], Olorunnisola et al. [11], and Carvajal et al. [41].

Limitations

The results of this study should be interpreted under the following limitations. First, this preclinical study included 52 Holtzman rats with a follow-up of 14 days; however, longer follow-ups (i.e., 3 to 4 weeks) must be carried out in order to know their toxic effects (subchronic or chronic) in longer exposure times to *Euphorbia huanchahana* (Klotzsch & Garcke) Boissier (*huachangana*). Second, a HPLC or GC/MS chromatographic analysis for the extraction and characterization of phytochemicals was not performed in this study. Third, although we performed hepatotoxicity testing, we did not assess the hematological

effects related to the toxic effects or other organ toxicity. It is key to know the changes in acute toxicity and macroscopic pathological injury in other organs.

5. Conclusions

In light of these findings, we can conclude that the extract of *Euphorbia huan-chahana* (Klotzsch & Garcke) Boissier (*huachangana*) is not toxic in the single dose of 2000 mg/kg investigated in this document and did not produce any toxic signs or symptoms with acute oral toxicity. The *Euphorbia huanchahana* (Klotzsch & Garcke) Boissier (*huachangana*) extract did not produce any notable histopathological signs of cell injury or cause any damage during the 14-day follow-up in Holtzman rats. These preliminary results highlight a nontoxic character and suggest a promising use of *Euphorbia huanchahana* (Klotzsch & Garcke) Boissier (*huachangana*) in the pharmaceutical and therapeutic fields. However, further research is needed to determine the toxic effects of long-term use, as well as the toxic effects in pregnant animals, animal fetuses, and effects on reproductive performance to complete the safety profile of this *Euphorbia* subspecies.

Author Contributions: Conceptualization, G.V., D.Ñ. and L.M.F.; methodology, A.G.R., E.R.T.-V., G.V. and D.Ñ.; validation, D.Ñ., A.G.R., E.R.T.-V. and L.M.F.; formal analysis, J.M.-S., G.V., D.Ñ. and L.M.F.; investigation, G.V., H.C.-P. and J.M.-S.; resources, G.V., D.Ñ. and L.M.F.; data curation, M.M.M.-S. and J.M.-S.; writing—original draft preparation, M.M.M.-S., H.C.-P. and J.M.-S.; writing—review and editing, M.M.M.-S., D.Ñ., L.M.F. and J.M.-S.; and project administration, J.M.-S. All authors have read and agreed to the published version of the manuscript.

Funding: This research received no external funding.

Institutional Review Board Statement: The animal study protocol was approved by the Institutional Review Board of Universidad Norbert Wiener (N° 0021-2018-FFB-UNW, 15 September 2018).

Informed Consent Statement: Not applicable.

Data Availability Statement: The data will be disclosed upon request to the authors.

Acknowledgments: We would like to thank Juana Chávez Flores, who supported us in the sampling and toxicity analysis, and the Nesh Hubbs team for their support in the data analysis.

Conflicts of Interest: The authors declare no conflict of interest.

Appendix A

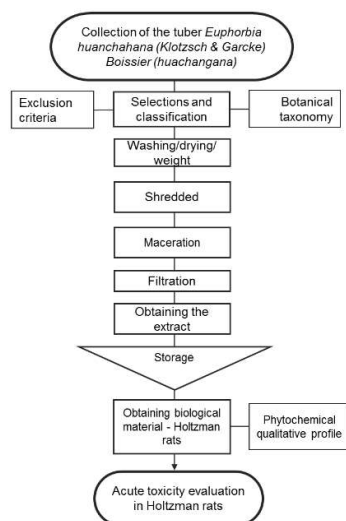


Figure A1. Flowchart for obtaining the ethanolic extract of *Euphorbia huanchahana* (Klotzsch & Garcke) Boissier (*huachangana*).

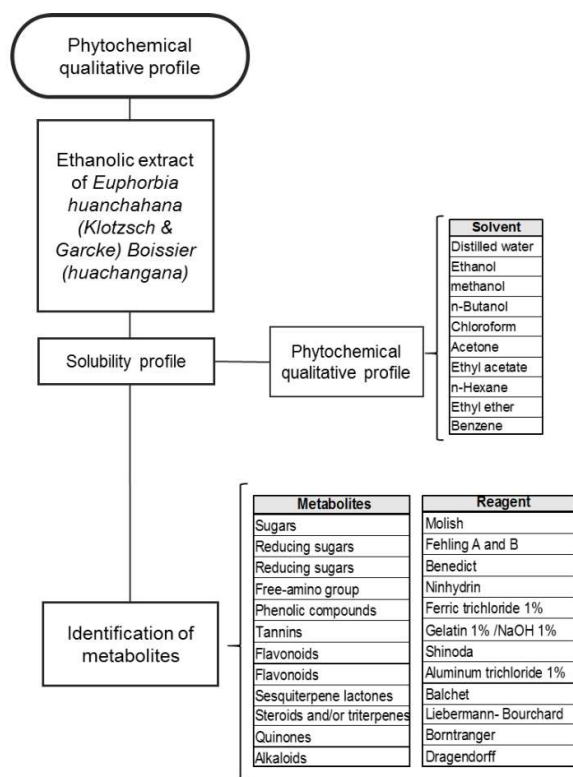


Figure A2. Analysis of the qualitative phytochemical profile of the ethanolic extract of *Euphorbia huanchahana* (Klotzsch & Garcke) Boissier (huachangana).

References

- Ghasemian, M.; Owlia, S.; Owlia, M.B. Review of Anti-Inflammatory Herbal Medicines. *Adv. Pharm. Pharmac. Sci.* **2016**, *2016*, 9130979. [[CrossRef](#)] [[PubMed](#)]
- Gupta, N.; Vishnoi, G.; Wal, A.; Wal, P. Medicinal Value of *Euphorbia Tirucalli*. *Syst. Rev. Pharm.* **2013**, *4*, 31–40. [[CrossRef](#)]
- Da Silva, S.; Oliveira, G.; Dias, R.; Alvarenga, M.R. Representaciones y usos de las plantas medicinales en mayores. *Rev. Latino-Am. Enfermagem.* **2018**, *20*, 778–786.
- Pauro, R.J.; Gonzáles, M.J.; Gamarra, C.B.M.; Pauro, J.R.; Mamani, F.; Huerta, R.B. Plantas Alimenticias, Medicinales y Biosidas de las Comunidades de Muñani y Suatia, Provincia de Lampa (Puno–Perú). *Ecol. Aplic.* **2011**, *10*, 41–49. [[CrossRef](#)]
- Lottus, J.O. Infusiones, tisanas o té de hierbas permitidas y nocivas durante el embarazo y la lactancia. *Rev. Obs. Ginecol.-Hosp. Santiago Oriente Dr. Luis Tisné Brousse.* **2015**, *10*, 148–159.
- Leiva, L.L.; Escobar, R.R.; Morales, J.A.; Sori, L.Y.; Escobar, V.E. Intoxicaciones agudas por plantas tóxicas reportadas por Centro de Toxicología de Villa Clara en período 2008–2011. *Rev. Cubana. Plant Med.* **2014**, *19*, 399–406.
- Ccama, C. Toxicología de Adsorción y Excreción. Master's Thesis, Escuela Académico Profesional de Ingeniería e Industrias Alimentaria, Facultad de Ingeniería de Procesos, Universidad Nacional de San Agustín de Arequipa, Arequipa, Peru, 2014.
- De Sousa, M.; Alves, S. Especies de interés de familia Euphorbiaceae en Brasil. *Rev. Cub. Plantas Med.* **2014**, *19*, 292–309.
- Silvero-Isidre, A.; Morínigo-Guayacán, S.; Meza-Ojeda, A.; Mongelós-Cardozo, M.; González-Ayala, A.; Figueredo-Thiel, S. Toxicidad Aguda de las hojas de *Xanthium spinosum* en ratones Balb/C. *Rev. Perú Med. Exp. Salud Pública* **2016**, *33*, 113–119. [[CrossRef](#)]
- Salazar, W.; Cárdenas, J.; Núñez, M.; Fernández, I.; Villegas, L.; Pacheco, L.; Untiveros, G. Estudio fitoquímico y de la actividad antihelmíntica de los extractos de *Euphorbia huanchahana* y *Baccharis salicifolia*. *Rev. Soc. Quim. Perú* **2007**, *73*, 150–157.
- Olorunnisola, O.; Adetutu, A.; Owoade, A.; Ajayi, F.; Ajibade, A.; Adegbola, P. Acute and Sub-acute Toxicity Assessment of *Euphorbia lateriflora* (Schum and Thonn) in Wistar Albino Rats. *Eur. J. Med. Plants.* **2019**, *29*, 1–10. [[CrossRef](#)]
- Ping, K.Y.; Darah, I.; Chen, Y.; Sreeramanan, S.; Sasidharan, S. Acute and Subchronic Toxicity Study of *Euphorbia hirta* L. Methanol Extract in Rats. *BioMed. Res. Int.* **2013**, *2013*, 182064. [[CrossRef](#)]
- Bussmann, R.; Sharon, D. *Medicinal Plants and Their Ecology in Northern Peru and Southern Ecuador*; Lila State University: Tbilisi, Georgia, 2015.
- Ñañez, D.; Mendoza, M.; Félix, L.; Rivas, W.; Mendoza, M.; Torres, E.R. Determinación de Fitoconstituyentes y evaluación de la actividad catártica en el extracto hidroalcohólico de *Euphorbia huanchahana* (Huachangana). *Rev. Perú Med. Integrativa.* **2018**, *3*, 71–77. [[CrossRef](#)]

15. Nogué, J.; Blanché, C.; Piqueras, J. *Intoxicación por Plantas y Setas*; Laboratorios Menarini S.A.: Barcelona, Spain, 2009.
16. Jian, W.; Liu, H. *Traditional Herbal Medicine Research Methods: Identification, Analysis, Bioassay, and Pharmaceutical and Clinical Studies*; Wiley: Hoboken, NJ, USA, 2011.
17. Lock, O. *Investigación Fitoquímica, Métodos en el Estudio de Productos Naturales*, 3rd ed.; Pontificia Universidad Católica del Perú: Lima, Peru, 2016.
18. Ramírez, A.; Isaza, G.; Pérez, J.; Martínez, M. Estudio fitoquímico preliminar y evaluación de la actividad antibacteriana del *Solanum dolichosepalum* bitter (Frutillo). *Rev. Cub. Plantas Med.* **2017**, *22*, 1–11.
19. Environmental Protection Agency. Health Effects Test Guidelines OPPTS 870.1100. In *Acute Oral Toxicity*; EPA 712–C–02–190; OECD Publishing: Washington, DC, USA, 2002.
20. National Research Council. *Guide for the Care and Use of Laboratory Animals*, 8th ed.; National Academies Press: Washington, DC, USA, 2011.
21. Organisation for Economic Cooperation and Development. *OECD Guideline for Testing of Chemicals, Test No. 423: Acute Oral Toxicity-Acute Toxic Class Method*; OECD Press: Paris, France, 2001. [[CrossRef](#)]
22. Gorriti, A.; Arroyo, J.; Quispe, F.; Cisneros, B.; Condorhuaman, M.; Almora, J.; Chumpitaz, V. Toxicidad oral a 60 días del aceite de sacha inchi (*plukenetia volubilis* L.) y linaza (*linum usitatissimum* L.) y determinación de la dosis letal 50 en roedores. *Rev. Peru Med. Exp. Salud Publica* **2010**, *27*, 352–360. [[CrossRef](#)]
23. Fuentes, F.; Mendoza, R.; Rosales, A.; Cisneros, R. *Guía de Manejo y Cuidado de Animales de Laboratorio*; Centro Nacional de Productos Biológicos, Instituto Nacional de Salud: Lima, Peru, 2008.
24. Torres, M.; García, E.; García, S.G.; Aradillas, C.; Cubillas, A. Evaluación de la toxicidad aguda In Vivo del extracto etanólico y acuoso de *Calea urticifolia*. *Bot. Sci.* **2016**, *94*, 133–140. [[CrossRef](#)]
25. Romero, W.; Zenia, B.Z.; De Lucca, M.; Ruano, A.; García, M.; Rivera, M.; García, J.; Sánchez, S. EL 1, 2, 3 de la Experimentación con Animales de Laboratorio. *Rev. Perú Med. Exp. Salud Pública* **2016**, *33*, 288–299. [[CrossRef](#)]
26. Moya, S.J.; Pio, D.L. Enzymatic biochemical parameters (ALT, AST, ALP, γ -GT, LDH) in children with acute lymphoblastic leukemia before antineoplastic treatment. *Horiz. Med.* **2015**, *15*, 51–58.
27. Cui, D.; Naftel, P.N.; Daley, W.P.; Lynch, J.C.; Haines, D.E.; Yang, G.; Fratkin, J.D. *Atlas of Histology with Functional and Clinical Correlations*, 1st ed.; Wolters Kluwer: Alphen aan den Rijn, The Netherlands, 2011; p. 482.
28. Culling, C.F.A. *Handbook of Histopathological and Histochemical Techniques*, 3rd ed.; Butterworth: London, England, 1974; pp. 489–490.
29. Ridditid, W.; Sae-Wong, C.; Reanmongkol, W.; Wongnawa, M. Antinociceptive activity of the methanolic extract of *Kaempferia galanga* Linn. in experimental animals. *J. Ethnopharm.* **2008**, *118*, 225–230. [[CrossRef](#)]
30. Gallegos, M. Las plantas medicinales: Principal alternativa para el cuidado de la salud, en la población rural de Babahoyo, Ecuador. *An. Fac. Med.* **2016**, *77*, 327–332. [[CrossRef](#)]
31. Espejo, D. Ensayo clínico de la Huachangana (*Euphorbia Huanchahana*) como purgante drástico. Bachelor Thesis, Facultad de Medicina Humana, Universidad Nacional Mayor de San Marcos, Lima, Peru, 1891.
32. Ramírez-Viena, L.; Mostacero-León, J.; De La Cruz-Castillo, A.J. Flora etnobotánica promisoría empleada por la comunidad de Cuspón, Ancash, Perú. *Manglar* **2019**, *16*, 125–131. [[CrossRef](#)]
33. Sharif, H.B.; Mukhtar, M.D.; Mustapha, Y.; Baba, G.; Lawal, A.O. Acute and Subchronic Toxicity Profile of *Euphorbia pulcherrima* Methanol Extract on Wistar Albino Rats. *Adv. Pharm.* **2015**, *9*, 2015. [[CrossRef](#)]
34. Arroyo, J.; Franco, C.; Chávez, R.; Anampa, A.; Rojas, J.; Cabanillas, J. Estudio de toxicidad a 28 días, del extracto atomizado de rizoma de *Curcuma longa* (a4r), flores de *Cordia lutea* (a4f) y hojas de *Annona muricata* (a4l) en un modelo murino. *Rev. Per. Med. Integrativa.* **2016**, *1*, 31–37.
35. Águila, J.; Bartra, J. Determinación sérica de Bilirrubina Directa Toral en Personas Adultas de Ambos Sexos Pertenecientes a la Iglesia Adventista de Trujillo. La Libertad-Julio; 2012. Master's Thesis, Universidad Nacional de Trujillo, Trujillo, Peru, 2012.
36. Sandoval, M.; Ayala, S.; Oré, M.; Valdivieso, L.; Loli, R.; Ricra, V.; Huamán, O. Evaluación de la toxicidad hepática y renal aguda y subaguda del látex de *Crotón palanostigma* (sangre de grado) en animales de experimentación. *An. Fac. Med.* **2005**, *66*, 119–126. [[CrossRef](#)]
37. Rojas, M. Valores de Referencia de Perfil Hepático y Lipídico en Personas que Viven a 3000 Metros Sobre el Nivel del Mar. Bachelor's Thesis, Universidad Técnica de Ambato, Ambato, Ecuador, 2019.
38. Miranda, A. Estudio Fitoquímico, y Evaluación de la Actividad Citotóxica y Antimicrobiana In Vitro del Látex de *Euphorbia laurifolia* en Patógenos Dérmicos. Master's Thesis, Escuela Superior Politécnica de Chimborazo, Riobamba, Ecuador, 2015.
39. Castillo, E.; Castillo, S.; Reyes, C. Estudio fitoquímico de *Plukenetia volubilis* L. y su efecto antioxidante en la lipoperoxidación inducida por Fe^{3+} /ascorbato en hígado de *Rattus rattus* var. *Albinus*. *Scientia* **2010**, *2*, 11–21.
40. Collave, H.; García, A. Estudio Farmacognóstico y Cuantificación de Flavonoides Totales en las Hojas de “Manihot esculenta” yuca. Master's Thesis, Universidad Nacional de Trujillo, Trujillo, Peru, 2014.
41. Carvajal, L.; Hata, Y.; Sierra, N.; Rueda, D. Análisis fitoquímico preliminar de hojas, tallos y semillas de cupatá (*Strychnos schultesiana* krukoff). *Rev. Col. For.* **2009**, *12*, 161–170. [[CrossRef](#)]