






# Imatinib use in the management of a patient with Doege–Potter syndrome

Jose Paz-Ibarra <sup>1,2</sup>, Jose Lu-Antara <sup>1,3</sup>, Brenda-Erendida Uscamayta <sup>1,3</sup>, Jhancy Martinez-Auris <sup>1,3</sup>,  
Miriam Valencia-Rivera <sup>1,3</sup>, Sofía Sáenz-Bustamante <sup>1,2</sup>, Marialejandra Delgado-Rojas <sup>1,2</sup>,  
Julia Salcedo-Vasquez <sup>1,2</sup> and Marcio Concepción-Zavaleta <sup>4</sup>

<sup>1</sup>Faculty of Medicine, National University of San Marcos, Lima, Peru, <sup>2</sup>National Hospital Edgardo Rebagliati Martins, Lima, Peru, <sup>3</sup>Scientific Society of San Fernando, Lima, Peru, and <sup>4</sup>Division of Endocrinology. School of Medicine, Norbert Wiener University. Lima, Peru

Correspondence  
should be addressed  
to J Lu-Antara  
**Email**  
[jose.lu1@unmsm.edu.pe](mailto:jose.lu1@unmsm.edu.pe)

## Summary

Doege–Potter syndrome (DPS) is a paraneoplastic syndrome characterized by nonislet cell tumor hypoglycemia due to a solitary fibrous tumor, which produces insulin-like growth factor II. In this report, we present the case of a 67-year-old male with recurrent and refractory hypoglycemia due to DPS successfully treated with imatinib. He initially presented with neuroglycopenic symptoms and dyspnea secondary to a giant tumor in the left hemithorax, which was totally resected. During follow-up, 7 years later, he presented with thoracoabdominal tumor recurrence associated with severe hypoglycemia and underwent subtotal tumor resection, with a subsequent improvement of symptoms. The following year, he had a recurrence of his intra-abdominal tumor, which was unresectable, associated with severe hypoglycemia refractory to dextrose infusion and corticosteroids, thus receiving imatinib with a favorable response. The clinical presentation, diagnostic approach, progression of the disease, and response to treatment with imatinib in the management of a patient with large, recurrent, and unresectable mesenchymal tumors with insulin-like growth factor-2 secretion causing hypoglycemia highlight the importance of this case report.

## Learning points

- Doege–Potter syndrome (DPS) is a rare cause of tumoral hypoglycemia of non-pancreatic origin.
- Some malignant or benign neoplasms have ectopic secretion of insulin-like growth factor-2.
- Total surgical removal is the principal treatment in patients with DPS.
- Tyrosine kinase inhibitors management in DPS may contribute to improved tumor control in patients with unresectable tumors and severe hypoglycemia.

## Background

Solitary fibrous tumor (SFT) is a very rare variant of soft tissue sarcoma. Its presentation is usually benign, and it is most commonly located in the pleural cavity (1). It generally manifests as a slow-growing, asymptomatic mass that recurs infrequently, and it could metastasize to the liver, lungs, or central nervous system (2). SFT may rarely have complications that are reasons for medical consultation, which include pulmonary hypertrophic

osteoarthritis or refractory hypoglycemia, the latter known as Doege–Potter syndrome (DPS).

DPS is a paraneoplastic syndrome characterized by severe and refractory hypoglycemia secondary to ectopic overproduction of insulin-like growth factor 2 (IGF2) by SFT and occurs in less than 5% of patients with SFT (3).

The definitive treatment for DPS is complete resection of the tumor. If the tumor is unresectable,

other therapeutic options could be implemented (4). Cases have been reported on the use of tyrosine kinase inhibitors (TKIs) that would have a favorable antitumor effect and in the control of hypoglycemia (5). However, to date, there is no consensus on the efficacy of these (5). We present the case of a patient with severe and refractory hypoglycemia due to recurrent SFT of malignant behavior treated with imatinib.

## Case presentation

A 59-year-old male patient was attended in another health institution due to dyspnea, neuroglycopenic symptoms, and the presence of a giant tumor in the left hemithorax. He underwent left pneumonectomy. Before operation, the patient reported 6 months of adrenergic symptoms and 2 weeks of neuroglycopenic symptoms. The tumor weighed 590 g, and the pathological study concluded SFT with immunohistochemistry positive for CD34 and Bcl-2 and negative for S-100. No postoperative imaging was performed.

Seven years later, he was admitted urgently to our hospital, with severe hypoglycemia and Whipple's triad. He reported a history of progressive dyspnea and early satiety. Table 1 shows the laboratory test results. As shown by computed tomography, a giant thoracoabdominal tumor occupied the left flank and measured 29 × 23 × 15 cm (Fig. 1). The treatment consisted of a fractional hypercaloric diet, dextrose infusion at 10% i.v., octreotide 300 µg/24 h s.c., and prednisone 20 mg/24 h; resection of an estimated 95% of the tumor was performed. The pathological study reported a 2.95 kg tumor measuring 39 × 31 × 22 cm. Typical features of an SFT are shown on microscopic examination (Fig. 2). In several sections examined, two mitoses were found in 10 high-power fields, no necrosis was seen, and the tumor compromised the surgical

margins. Immunohistochemistry was positive for CD34, weakly positive for CD99, and negative for S-100; the mitotic index Ki-67 was <5%.

Immunohistochemistry for IGF2 was not available. The patient reported a notable decrease in hypoglycemic episodes and was discharged with a split diet, prednisone 10 mg/24 h, and glucose self-monitoring. The patient stated that 6 weeks after discharge, he discontinued corticosteroid use, without presenting episodes of hypoglycemia. He did not return for outpatient assessment.

## Investigation

The following year, the patient was admitted for presenting a rapidly growing, painful abdominal tumor associated with severe hypoglycemia confirmed via Whipple's triad of a few weeks' duration that partially improved with an increase in sugar intake, meal frequency, and prednisone resumption. An asymmetric abdomen, a median scar, and prominence from the left hypochondrium to the left flank were demonstrated, where a hard tumor was palpated with an irregular surface and mild pain on palpation (Fig. 3). Table 1 shows the laboratory test results. Abdominal tomography showed a large, extensive retroperitoneal infiltrating tumor (Fig. 4).

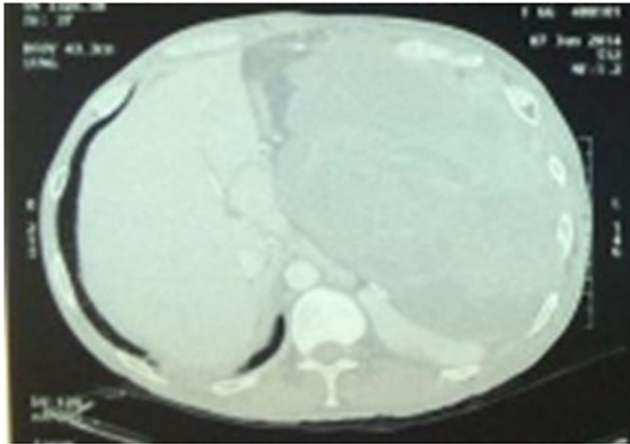
## Treatment

As per the conclusion of the multidisciplinary medical board, the patient did not require a new surgical intervention due to the size, extension, and infiltration of soft tissues. His treatment included 50% dextrose infusion, prednisone 20 mg/24 h, and hypercaloric nutritional support. The endocrinology workup team decided to

**Table 1** Laboratory analysis performed before and after thoracoabdominal surgery in 2014 and at readmission in 2015.

Blood tests	Preoperative values	Postoperative values	Values at medical consultation	Reference range
Glucose (mg/dL)	30–50	80–110	30–75	70–100
Free thyroxine (pg/mL)	0.83	NA	NA	0.8–1.9
TSH (mIU/mL)	4.01	NA	NA	0.4–4
Morning plasma cortisol (µg/dL)	17	NA	NA	5–25
Basal GH (ng/mL)	0.058	NA	NA	<3
C-peptide (ng/mL)	0.59	0.43	<0.1	0.9–7.1
Insulin (µIU/mL)	<2	<2	<2	9.3–29.1
IGF1 (ng/mL)	144	193	98	69–200
IGF2 (ng/mL)	398	NA	NA	50–250

GH, growth hormone; IGF1, insulin-like growth factor 1. IGF2, insulin-like growth factor -2; NA, not available; TSH, thyroid-stimulating hormone.



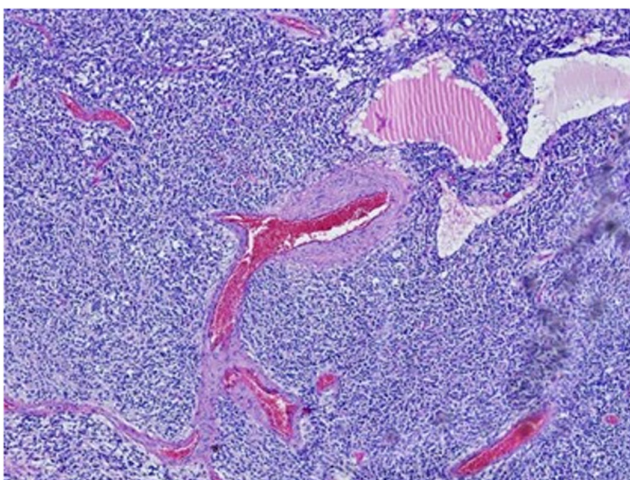
**Figure 1**

Axial section of abdominal computed tomography with contrast performed in 2014, showing a large tumor of 29 × 23 × 15 cm, which extends from the left hypochondrium to the left flank.

start treatment with imatinib 400 mg/24 h orally, with adequate tolerance and better glycemic control, as verified by fasting blood glucose levels of 85–111 mg/dL.

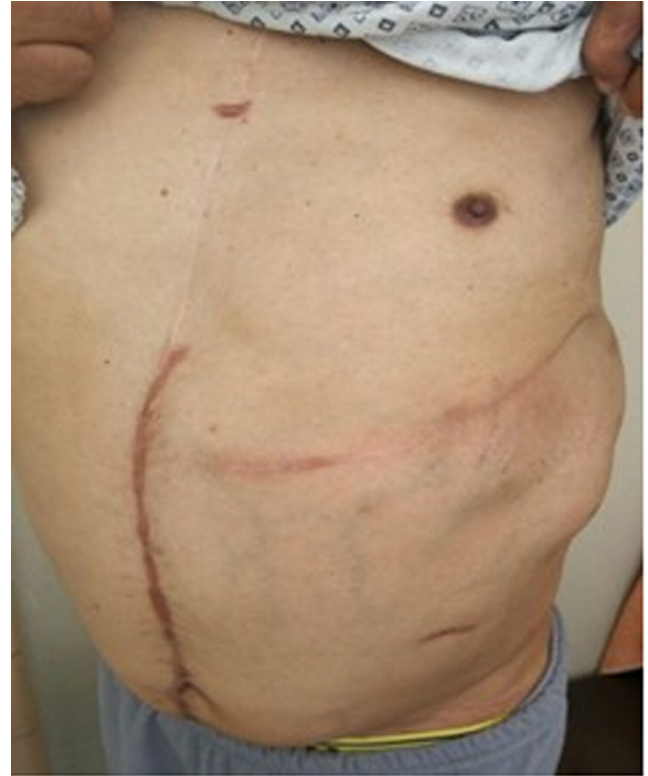### Outcome and follow-up

The patient was discharged with indication plan for external radiotherapy and to continue with imatinib. The patient follow-up was carried out via telemedicine. From the patient's and his relative's perspective, the tumor volume decreased and the pain decreased, but the sensation of early fullness persisted. He did not receive



**Figure 2**

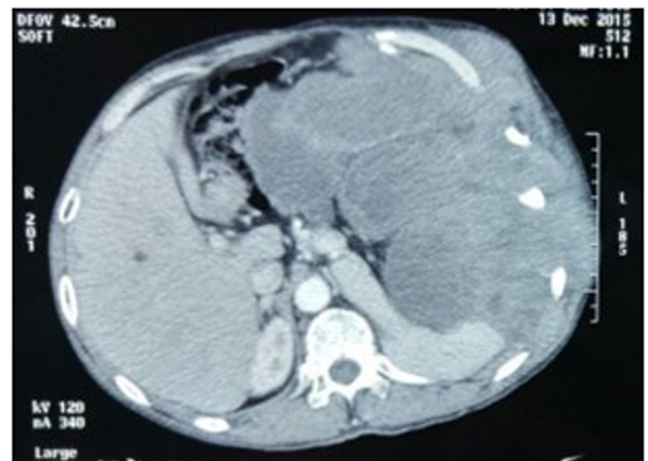
Microscopic view of the tumor, which reveals round cell proliferation with mild atypia, fibrous stroma, with areas of adipose differentiation and angiomatous vascular pattern, confirming the diagnosis of solitary fibrous tumor.



**Figure 3**

A prominence is observed at the level of the left side of the abdomen, caused by the presence of an abdominal tumor.

radiotherapy sessions for geographical and family reasons. He continued using prednisone for a few weeks and then remained on imatinib and nutritional management with no reports of hypoglycemic symptoms during the 12-month follow-up, after which they did not recur during



**Figure 4**

Axial section of abdominal computed tomography with contrast performed in 2015, where an extensive retroperitoneal tumor infiltrated to the chest wall is observed.



his outpatient controls in our specialty. The family reported his death 2 years after his discharge. The cause is unknown, and as based on the family's report, he developed a severe consumptive syndrome associated with moderate-to-severe pain.

## Discussion

SFT is a very rare type of mesenchymal cell-derived neoplasm that accounts for less than 2% of all known cases of soft tissue sarcoma patients. Patients with SFT are usually asymptomatic; however, they may have symptoms due to compression of adjacent structures depending on the location and size of the tumor (1). In this case, the first presentation of the SFT was in the pleura and was accompanied by dyspnea, and the second presentation was at the retroperitoneal location, due to a palpable tumor with an irregular and painful surface in the abdomen.

DPS is a rare phenomenon and is due to the overproduction of IGF2 and its precursor, 'big' IGF2, produced by the tumor, which exerts negative feedback on the production of growth hormone (GH) by the pituitary gland, thus decreasing the production of GH-dependent peptides, including IGF1. Therefore, the IGF2/IGF1 ratio is considered a diagnostic criterion (6). In a healthy person, the normal value of this ratio is 3 to 1; however, in DPS, this value can increase to more than 10 to 1. In the present case, IGF2 was elevated, while IGF1 was within normal values; the IGF2/IGF1 ratio was near the upper limit.

It was observed in a review of 76 cases of DPS that the nature of these neoplasms has been more frequently malignant (60.6%), contrary to what was previously published in the literature (5–10.4%) (6). Several models have been proposed to predict the malignancy of SFTs. According to England *et al.*, since this is a tumor larger than 10 cm in all its dimensions, it would be considered malignant with a high risk of recurrence (7). Diebold *et al.* proposed a new scoring system for pleural SFT to define the malignancy of the tumor considering histological and anatomical markers and, additionally, the MIB1/KI67 biomarker, which is an important prognostic factor of adverse outcomes in patients with pleural SFT (8). This patient has an MIB1/Ki67 index below 5%.

Complete surgical resection of the tumor is the definitive treatment for SFT and DPS and can prevent the recurrence of this tumor (8). It has been described that of 86 patients who underwent surgical resection, 49 (57%) presented recurrence, 23 (27%) developed recurrence,

and 26 (30%) had metastases (1). Therefore, continuous monitoring of the postoperated patient is necessary to detect early the development of tumor recurrence. Our patient presented two recurrences: the first one was approximately 7 years after the left pneumonectomy and the second one was a year after the almost complete resection of the tumor in our center.

Although there is no standard treatment for DPS, management is individualized. If it is not cured with surgery, chemotherapy, or chemoembolization, among others, could be opted for. Chen *et al.* reported a good clinical response to the combination of dacarbazine plus bevacizumab in a 44-year-old male patient with DPS and a history of remitted intra-abdominal diffuse large B cell lymphoma (9). Furthermore, Park *et al.* described a retrospective cohort of 14 patients with hemangiopericytomas and SFT treated with the combination of temozolomide plus bevacizumab, obtaining a response rate of 79% based on tomographic findings (10).

Cases have been reported in which TKI or antiangiogenic agents were used (11). TKIs such as imatinib, dasatinib, sorafenib, sunitinib, and pazopanib are known to be used to treat malignancies such as chronic myeloid leukemia, renal cell carcinoma, and gastrointestinal stromal tumor (5, 12). In our patient, imatinib was used with likely control of his hypoglycemia and subjectively reduction in tumor volume, which allows a partial response to treatment with imatinib in our patient, according to the Choi criteria (13).

The antitumor effects of imatinib are mainly mediated by its inhibition of the tyrosine kinase domain of the Bcr-Abl oncoprotein. The glycemic mechanisms and effects remain unclear and controversial. Nicole *et al.* reported that TKIs could induce hypoglycemia in both diabetic and nondiabetic patients. Our patient improves his blood sugar levels possibly due to targeted c-kit receptor and platelet-derived growth factor receptor (5). In our patient, the results obtained with imatinib may be explained by its antitumor effects rather than by its metabolic effects, although to confirm this, more studies about identifying other undefined targets would be needed.

---

### Declaration of interest

The authors declare that there is no conflict of interest that could be perceived as prejudicing the impartiality of the research reported.

---

### Funding

This work did not receive any specific grant from any funding agency in the public, commercial, or not-for-profit sector.



### Patient consent

Written informed consent for publication of their clinical details and clinical images was obtained from the patient.

### Author contribution statement

All authors were involved in patient care. M Valencia-Rivera searched the literature. J Paz-Ibarra, J Lu-Antara, B Uscamayta, and J Martinez-Auris were responsible for conceptualizing and drafting the manuscript. S Sáenz-Bustamante, M Delgado-Rojas, J Salcedo-Vasquez, and M Concepción-Zavaleta reviewed and edited the manuscript.

### Acknowledgements

The authors would like to thank Enago (www.enago.com) for the English language review.

## References

- Schöffski P, Timmermans I, Hompes D, Stas M, Sinnaeve F, De Leyn P, Coosemans W, Van Raemdonck D, Hauben E, Sciot R, *et al.* Clinical presentation, natural history, and therapeutic approach in patients with solitary fibrous tumor: a retrospective analysis. *Sarcoma* 2020 **2020** 1385978. (<https://doi.org/10.1155/2020/1385978>)
- Ceballos MEGD, Hernández-Solis A, Cruz-Ortiz H, González-Atencio Y & Cicero-Sabido R. Solitary fibrous tumor. Clinic and pathological study of 16 cases. *Cirugía y Cirujanos* 2011 **5** 8.
- Solsi A, Pho K, Shojaie S, Findakly D & Noori T. Doege-Potter syndrome and Pierre-Marie-Bamberger syndrome in a patient with pleural solitary fibrous tumor: a rare case with literature review. *Cureus* 2020 **12** e7919. (<https://doi.org/10.7759/cureus.7919>)
- De Boer J, Jager PL, Wiggers T, Nieboer P, Machteld Wymenga AN, Pras E, Hoogenberg K, Sleijfer DT, Suurmeijer AJH & van der Graaf WT. The therapeutic challenge of a nonresectable solitary fibrous tumor in a hypoglycemic patient. *International Journal of Clinical Oncology* 2006 **11** 478–481. (<https://doi.org/10.1007/s10147-006-0606-1>)
- Agostino NM, Chinchilli VM, Lynch CJ, Koszyk-Szewczyk A, Gingrich R, Sivik J & Drabick JJ. Effect of the tyrosine kinase inhibitors (sunitinib, sorafenib, dasatinib, and imatinib) on blood glucose levels in diabetic and nondiabetic patients in general clinical practice. *Journal of Oncology Pharmacy Practice* 2011 **17** 197–202. (<https://doi.org/10.1177/1078155210378913>)
- Han G, Zhang Z, Shen X, Wang K, Zhao Y, He J, Gao Y, Shan X, Xin G, Li C, *et al.* Doege–Potter syndrome: A review of the literature including a new case report. *Medicine (Baltimore)* 2017 **96** e7417. (<https://doi.org/10.1097/MD.0000000000007417>)
- England DM, Hochholzer L & McCarthy MJ. Localized benign and malignant fibrous tumors of the pleura. A clinicopathologic review of 223 cases. *American Journal of Surgical Pathology* 1989 **13** 640–658. (<https://doi.org/10.1097/00000478-198908000-00003>)
- Diebold M, Soltermann A, Hottinger S, Haile SR, Bubendorf L, Komminoth P, Jochum W, Grobholz R, Theegarten D, Berezowska S, *et al.* Prognostic value of MIB-1 proliferation index in solitary fibrous tumors of the pleura implemented in a new score – a multicenter study. *Respiratory Research* 2017 **18** 210. (<https://doi.org/10.1186/s12931-017-0693-8>)
- Chen CT, Lee JC, Huang SC & Chen TW. Dacarbazine and bevacizumab improved paraneoplastic Doege–potter syndrome of malignant solitary fibrous tumor. *Journal of Cancer Research and Practice* 2021 **8** 68–72. ([https://doi.org/10.4103/JCRP.JCRP\\_27\\_20](https://doi.org/10.4103/JCRP.JCRP_27_20))
- Park MS, Patel SR, Ludwig JA, Trent JC, Conrad CA, Lazar AJ, Wang WL, Boonsirikamchai P, Choi H, Wang X, *et al.* Activity of temozolomide and bevacizumab in the treatment of locally advanced, recurrent, and metastatic hemangiopericytoma and malignant solitary fibrous tumor. *Cancer* 2011 **117** 4939–4947. (<https://doi.org/10.1002/cncr.26098>)
- Bodnar TW, Acevedo MJ & Pietropaolo M. Management of non-islet-cell tumor hypoglycemia: a clinical review. *Journal of Clinical Endocrinology and Metabolism* 2014 **99** 713–722. (<https://doi.org/10.1210/jc.2013-3382>)
- Martin-Broto J, Stacchiotti S, Lopez-Pousa A, Redondo A, Bernabeu D, Alava de E, Casali PG, Italiano A, Gutierrez A, Moura DS, *et al.* Pazopanib for treatment of advanced malignant and dedifferentiated solitary fibrous tumor: a multicentre, single-arm, phase 2 trial. *Lancet. Oncology* 2019 **20** 134–144. ([https://doi.org/10.1016/S1470-2045\(18\)30676-4](https://doi.org/10.1016/S1470-2045(18)30676-4))
- Choi H, Charnsangavej C, Faria SC, Macapinlac HA, Burgess MA, Patel SR, Chen LL, Podoloff DA & Benjamin RS. Correlation of computed tomography and positron emission tomography in patients with metastatic gastrointestinal stromal tumor treated at a single institution with imatinib mesylate: proposal of new computed tomography response criteria. *Journal of Clinical Oncology* 2007 **25** 1753–1759. (<https://doi.org/10.1200/JCO.2006.07.3049>)

Received 6 September 2022

Accepted 16 March 2023

Version of Record Published 21 April 2023